

Stereotactic radiosurgery

LARS LEKSELL

"ENCLOSURE"

#1

Occasional review

Stereotactic radiosurgery

LARS LEKSELL

From the Department of Neurosurgery, Karolinska Sjukhuset, Stockholm, Sweden

SUMMARY The development and scope of stereotactic radiosurgery is described. The technique, which combines well with the latest diagnostic methods, has already proved a safe and effective way of treating inaccessible cerebral lesions and in particular small arteriovenous malformations, acoustic neuroma and the solid component of craniopharyngioma, as well as playing an increasingly useful role in the therapy of pituitary adenoma.

Stereotactic radiosurgery is a technique for the non-invasive destruction of intracranial tissues or lesions that may be inaccessible or unsuitable for open surgery. The open stereotactic method provides the basis for radiosurgery and the first stereotactic instrument was designed for use with probes and electrodes.¹ The principle of the instrument, with the target in the centre of a semicircular arc, made it easily adaptable for cross-firing of the target with narrow beams of radiation. The first attempt to supplant the electrodes with ionizing radiation was made in the early fifties, with X-rays.^{2,3} It was tempting to try to reduce the hazards of open surgery and by the administration of a single heavy dose of radiation it appeared possible to destroy any deep brain structure, without risk of bleeding or infection.

Ten years later considerable progress had been made, due in considerable measure to the contribution of the physicists Kurt Liden and Borje Larsson, and fig 1 shows the first proton beam operation in Uppsala.⁴⁻⁶ The heavy particle beam was an excellent knife blade but the synchro-cyclotron was too clumsy. A similar technique was developed for a linear accelerator. The next step was to get to a practical, precise and simple tool which could be handled by the surgeon himself.

The first stereotactic Gamma Unit, using Cobalt 60 (fig 2), was installed at the Sophiahemmet Hospital in 1968 and was primarily intended for use in functional brain surgery for the section of deep fibre tracts or nuclei.^{7,8} The lesions were disc shaped and



Fig 1 Stereotactic proton beam operation. A bilateral anterior capsulotomy performed at the Gustaf Werner Institute in Uppsala in 1960.

very sharply circumscribed⁹ (fig 3). This apparatus was also used for the irradiation of some tumours and arteriovenous malformations.^{10,11} The results were promising and a second Gamma Unit, with more generally suitable spherical fields of radiation, was constructed and installed at the Karolinska Hospital in Stockholm in 1974. This machine was still, in some respects, a prototype, but it has proved very reliable and easy to use.

The relatively slow development of radiosurgery has been due partly to the absolute need for a precise localisation of the target. Many problems have been solved by the arrival of the new imaging techniques. However, the varying nature of the targets

Address for reprint requests: Prof. Lars Leksell, Karolinska Sjukhuset, Stockholm, Sweden.

Based on a Sir Hugh Cairns Memorial Lecture delivered in 1981 at a meeting of the Society of British Neurological Surgeons.

Received 25 March 1983 and in revised form 13 April 1983.
Accepted 16 April 1983

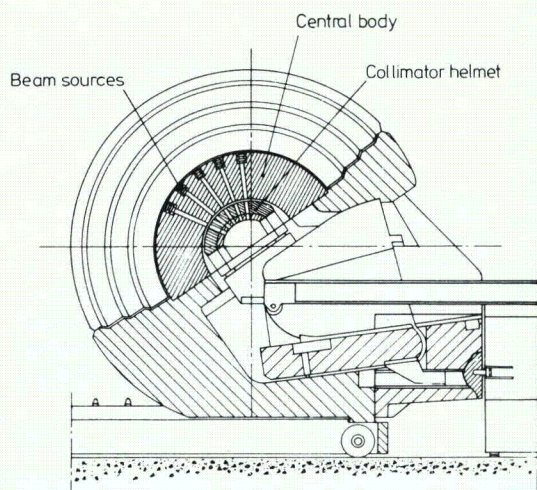


Fig 2 Sectional diagram showing principle of cross-firing of target with narrow beams of gamma rays from multiple cobalt sources.

requires a flexible approach to the localisation and at present several different diagnostic methods are used.

The standard radiographic procedure in the

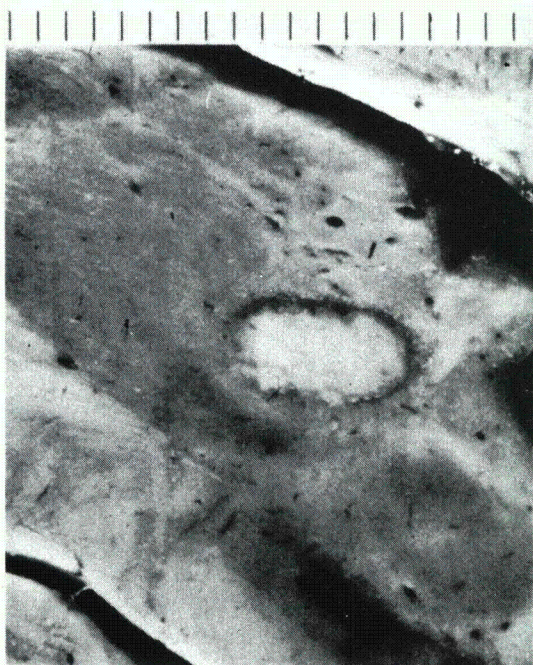

Fig 3 Gamma thalamotomy. Radiosurgical lesion in a patient with intractable cancer pain. Medial thalamus, section 30° posterior to coronal plane. Scale in mm. Unstained formalin fixed brain.

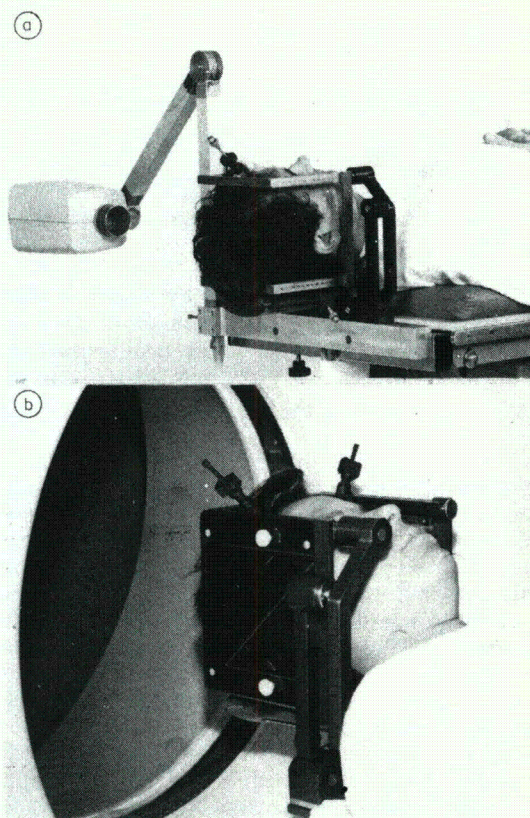


Fig 4 (A) stereotactic radiographic localisation in the operating theatre. AP and lateral views are made and the localisation procedure can be performed in any operating room. (B) Stereotactic CT localisation. The coordinate frame is fixed to the table by means of a magnetic adaptor. Plastic indicator discs are temporarily mounted on the frame for the determination of the target coordinates.

operating room, when plain radiographs or air-encephalography are used, remains very useful (fig 4A). A geometric diagram⁷ corrects the distortion due to the short-distance projections and allows rapid determination of the co-ordinates. In some instances, particularly when angiography is used, a stereophotogrammetric technique may be preferable. The target co-ordinates on the proximal and distal scales of the co-ordinate frame are then read off the film and fed into a small calculator. The correct co-ordinates are computed automatically and recorded on a printer.

The introduction of computer tomography has produced a revolution in stereotactic localisation. The early EMI-scanner was used for this purpose by Bergström and Greitz¹² and now CT localisation has become the most common procedure (fig 4B). The

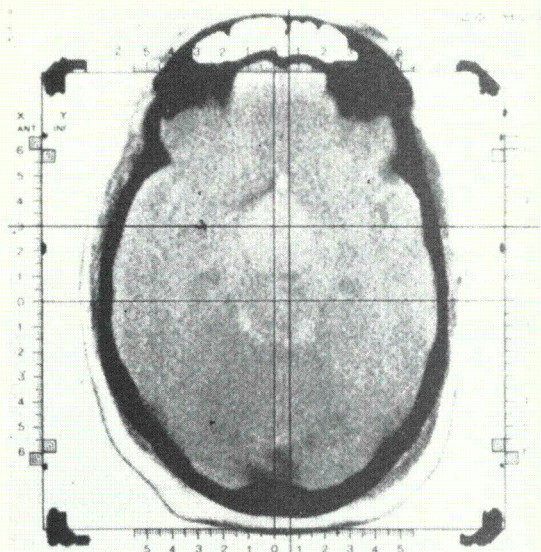


Fig 5 CT localisation of a cystic craniopharyngioma. The film is superimposed on a transparent millimeter scale and the target coordinates are read off with a ruler.

CT film is placed on a semitransparent disc with co-ordinate millimetre scales, and all three co-ordinates are easily read off (fig 5).¹³

When the single X-ray or proton beam was used the target was cross-irradiated by adjusting the position of the patient's head. In the Gamma Unit the head is rigidly fixed in the collimator helmet. This simplifies the procedure and ensures high mechanical accuracy. When the stereotactic localisation of the target and dose planning have been completed the patient is transferred to the unit and the head is fixed so that the target structure is in the centre of the helmet (fig 6). The irradiation procedure is easily performed by the surgeon, with one assistant.

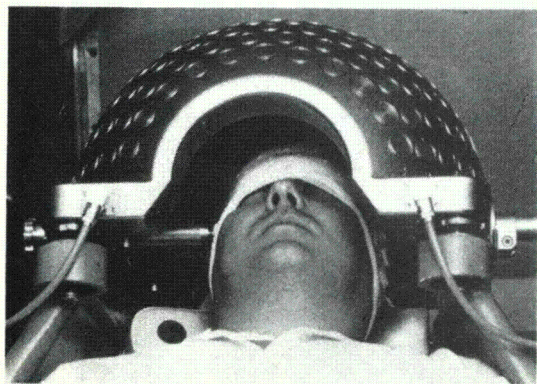


Fig 6 Fixation of the patient's head in the collimator helmet for the treatment of a right-sided acoustic tumour.

General anaesthesia is not required unless the patient is unusually apprehensive or restless, and, usually, the patient can leave the hospital directly after the operation if this is considered appropriate.

Clearly, the clinical results obtained must serve as the basis for the evaluation of the method and for future planning long term follow-up studies are necessary. Inevitably, before the full effects of single dose radiation were known, the early selection of patients was somewhat arbitrary and over the years a number of improvements have been made in technique and dose planning. At present more than 700 patients have been treated radiosurgically and most of the applications and results have been published.^{14-21 23 24 26 27}

For a long time stereotaxis was largely identified with functional brain surgery. Now this field represents a relatively small sector. The surgery of pain will probably remain and the early group of gamma-thalamotomies for intractable cancer pain gave much valuable information concerning the anatomy of the lesions and the dose of radiation required.^{14 15} Medial thalamotomy offered an attractive possibility of obtaining pain relief without sensory loss. The clinical results were somewhat inconsistent and usually of limited duration, although more effective for the relief of pain in the upper part of the body. Now, with a greater knowledge of the functional anatomy, this theme may well be taken up again, perhaps even as an out-patient procedure.

The advantages of radiosurgery were obvious in the gamma capsulotomies performed for severe anxiety and obsessive-compulsive states, but this field is small and psychosurgery meets much opposition from ideologists in Sweden and elsewhere in the world.

The functional visualisation obtainable by means of the positron camera or nuclear magnetic resonance may lead to further changes in the whole field of functional stereotaxy. For example, deep epileptic foci could become targets for stereotactic irradiation.

Today stereotactic techniques have become part of the general neurosurgical armamentarium and, at the Karolinska, about 25% of all the operative procedures are stereotactic, and of these about half are radiosurgical. Table 1 shows the number of patients in the various diagnostic groups. At present stereotactic radiosurgery is most commonly used for vascular malformations, acoustic tumours and craniopharyngiomas. The last-named form a particularly interesting group because of the combination of open and closed stereotactic techniques and all three groups illustrate well the way that stereotactic treatment can complement more conventional surgery. For example, the successful extir-

Table 1 Stereotactic radiosurgery 1968–1982

Arterio-venous malformation	204
Arterial aneurysm	5
Acoustic tumour	94
Craniopharyngioma	22
Meningioma	20
Pineal tumours	23
Pituitary adenoma (non-secreting)	37
Cushing's disease	95
Acromegaly	27
Hypophysectomy	24
Intractable pain	83
Trigeminal neuralgia	63
Anxiety and obsessive-compulsive states	26
Parkinsonism	5
Various	34
Total number of patients	762

Table 2 Stereotactic treatment of craniopharyngiomas 1966–1980 (Predominantly cystic tumours (1–2 cysts), intracystic⁹⁰Y)

	Tumour not previously treated	Recurrent tumour after previous surgery
Alive and well	29	16
Operative mortality	0	2
Recurrences	0	0
Later deaths	3*	1†
No follow-up	2	1
	34	20 N = 54

*Stroke 1, hepatitis 1, leukaemia 1, (Necropsy, 2 cases: complete shrinkage of cysts)

†Cardiac infarction

Backlund, 1980

pation of a craniopharyngioma requires dexterity and long surgical training. Moreover their relative infrequency makes it difficult for all surgeons to obtain sufficient experience. In the majority of cases the symptoms are due to the expanding cyst, and obliteration of the cystic parts by isotope injection¹⁸ solves most of the clinical problems. In a review of a

15 year material¹⁹ good results were obtained in 54 patients treated by stereotactic Yttrium 90 injection alone (table 2). This is followed by a gradual shrinkage and eventually a collapse of the cyst. Solid and multicystic tumours are best treated by external stereotactic irradiation²⁰ and the sharp limitation of the radiation field in the Gamma Unit is a considerable advantage. The resultant shrinkage can be followed easily by CT (fig 7). This combined intracystic and precise external irradiation has proved satisfactory and the results do not depend on a skilled surgeon practising his technique frequently.

Since 1975 95 patients with Cushing's disease and Nelson's syndrome have been treated by gamma irradiation.²¹ Small and spatially well defined volumes of tissue in the pituitary gland can be selectively destroyed. With the smallest collimator a kind of intrasellar "micro-radiosurgery" is possible. In a review of 37 patients with an observation time of more than one year, complete remission was obtained in 29 cases. This is a promising result. An important need is to find a satisfactory method for precise localisation of the small intrasellar tumours.

The treatment of acoustic tumours makes a fascinating historical chapter. When Folke Henschen wrote his thesis in 1910, 34 out of 42 patients collected had died from the operation. Fifty years ago Hugh Cairns read a paper in the Royal Society of Medicine, which demonstrated his surgical skill and the efforts required at that time for radical removal with conservation of the facial nerve.²² This operation still represents a surgical challenge and in small and medium sized tumours stereotactic gamma irradiation is a practical alternative. Hitherto 94 patients with acoustic tumours have been treated and a follow-up study of the first two groups operated upon with the first unit in Sophiahemmet and

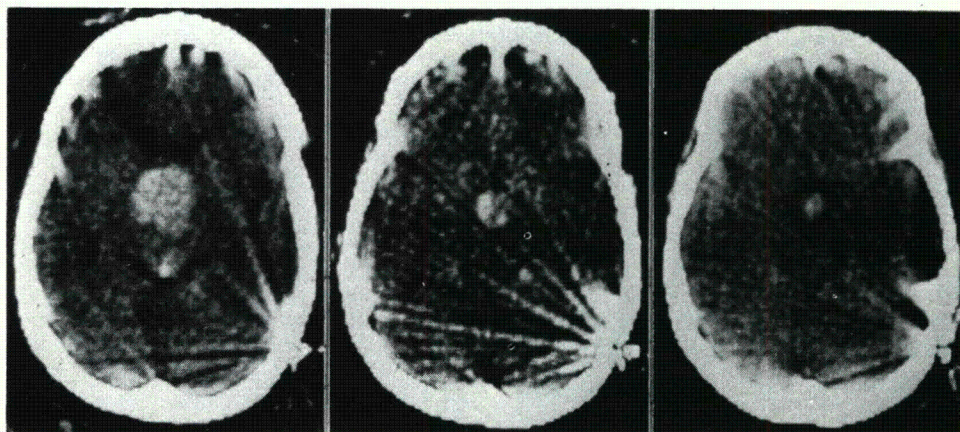


Fig 7 Stereotactic radiosurgery for solid craniopharyngioma. Left: preoperative scan, middle and right: postoperative controls 6 and 18 months after the operation. (Backlund 1980).

Table 3 Stereotactic radiosurgery in acoustic tumours (Patients treated at Sophiahemmet with gamma irradiation exclusively)

Pat	Sex/Age (yr)	Follow-up period (Yr)	Tumour size (mm)	Speech discrimination score initial	last follow-up	Cranial nerve function (8th nerve excl)	Functional status	Comments
1	F/34	11	12	70%	Deaf	Normal	Normal	Bilat tumours, the left-sided treated in Unit II (see text)
2	F/54	8	24	64%	34%	Normal	Retired due to age	
3	F/48	7	14	96%	42%	Slight facial hypoaesthesia; transient EMG signs	Normal	
4	F/56	6	10	78%	22%	Normal	Normal	Re-irradiation in Unit II
5	M/54	7	13	58%	14%	Normal	Retired due to age	
6	M/39	7	10	2%	Deaf	Normal	Normal	
7	M/61	5	9	40%	2%	Normal	Retired due to age	

with the second at the Karolinska, respectively, has been published.²³ The small group of patients with acoustic neuroma treated at the Sophiahemmet, (table 3) who have been followed for a sufficiently long period (up to 12 years), illustrated the possibilities and problems inherent with this technique. Following a sufficient dose of radiation the necrotic tumour tissue usually shrinks slightly but a mass remains. If the dose has been too small the tumour may start to grow again, even after a long latency, and then has to be re-irradiated or operated on conventionally. Facial weakness may occur but so far it has always been transient. Hearing is often preserved, at least to some extent.²⁴ The first patient in the series is of particular interest. She had bilateral tumours, with a strong family history (her father, one brother and two children also had bilateral tumours). The technique was not yet fully developed and one segment of the right sided tumour received too low a dose. This tumour started to grow again and nearly 12 years later it was removed surgically with a resulting facial paralysis. Re-irradiation would probably have been a better alternative. In order to evaluate fully the relative merits of open excision or stereotactic radiation of acoustic neuroma further experience is needed. However, even an experienced and skilful surgeon might have difficulty in reproducing the results obtained with radiosurgery: that is to say no operative mortality, no permanent facial weakness and in some cases preservation of hearing. Nowadays, CT scanning has much improved localisation and the treatment is almost an out-patient procedure. Furthermore, conventional surgery is not precluded if required later. The policy at the Karolinska is to use stereotactic radiosurgery in the first instance, for neurinomas

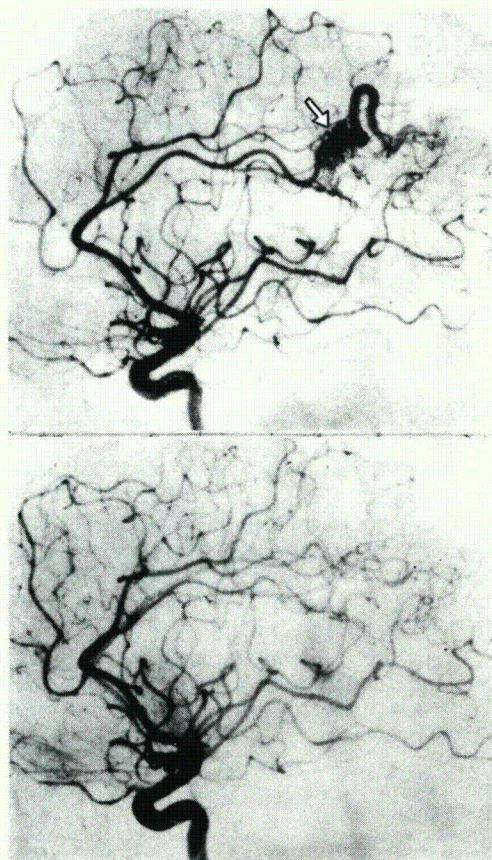


Fig 8 Stereotactic radiosurgery for arteriovenous malformation. Preoperative angiogram and control angiogram 2 years later.

measuring up to 25 mm in diameter. Several questions remain to be answered, particularly the relative radiosensitivity of the cochlear nerve and the optimal dose for destruction of the tumour with preservation of hearing.

So far 204 patients with arteriovenous malformations have been treated with stereotactic radiosurgery. In the first patient only the feeding arteries were irradiated.¹¹ This attempt preceded by far any rational knowledge concerning the effect of a single heavy dose of gamma radiation on arteries, and it was a shot in the dark. Despite this, the selective irradiation of the feeding vessels succeeded in this first case. Some experiments on the basilar artery of the cat showed how difficult it may be to obliterate a large healthy artery by irradiation alone.²⁵ However, from the first clinical trials a satisfactory technique for the treatment of small deep AVM's has emerged.^{26, 27} In a series of 67 patients followed for two years, where the fields of radiation covered the whole malformation, there was total obliteration of the pathological vessels in 83% of cases (table 4). The long latency of at least 6 to 18 months before obliteration is a disadvantage but the risk with radiosurgery in small, deep-seated, often inoperable AVM's is extremely small. There were only five cases of mild hemiparesis following stereotactic irradiation in the whole group of 204 patients.

In conclusion, it seems clear now that a first period of tentative development of radiosurgery has come to an end. The technique has been reviewed, some much needed improvements have been made and a new improved Gamma Unit has been constructed.

The term stereotactic radiosurgery has been used deliberately to stress the fact that this combination of mechanically directed instruments and modern radiation physics is still surgery, albeit using another physical agent in place of the knife or radiofrequency heat lesion. Indeed, the scalpel has never had a dominating place in the surgical handling of the brain, at least not since the introduction of diathermy. The Gamma Unit merely represents a change in the type of energy used. Modern neurosurgery should not rely on the open visual methods alone but must also incorporate the newer techniques. In this way the use of narrow beams of

ionizing radiation has little to do with radiotherapy in its conventional meaning, but the communication lines between the territories must remain open. In the same way there should be no sharp demarcation line with microsurgery; the same condition may be treated best in one patient with microsurgery and in another by stereotaxy. Maybe the most important lesson learnt at the Karolinska is that the simplicity of using the Gamma Unit makes this integration possible and that the same individual can be a competent microsurgeon and also a stereotactic radiosurgeon. Someone competent in both techniques is best fitted to decide where the boundaries between the two methods should lie.

A new impetus has been given to stereotaxy in general by the new imaging techniques such as CT, PET, ultrasound and particularly NMR, and these modern, non-invasive diagnostic techniques are particularly compatible with bloodless stereotactic radiosurgery. The two prototype radiosurgical units have functioned very well and the third generation units should be more effective and still easier to work with. Radiosurgery has established its efficacy and safety and offers an operative system which, combined with sophisticated modern diagnostic methods, makes the depths of the brain more accessible.

References

- ¹ Leksell, L. A stereotaxic apparatus for intracerebral surgery. *Acta Chir Scand* 1949;**99**:229-33.
- ² Leksell, L. The stereotaxic method and radiosurgery of the brain. *Acta Chir Scand* 1951;**102**:316-9.
- ³ Leksell, L., Herner T., Liden K. Stereotaxic radiosurgery of the brain. Report of a case. *Kungl. Fysiograf Sällsk Lund Förhandl* 1955;**25**(17):1-10.
- ⁴ Larsson B., Leksell L., Rexed B., Sourander P., Mair W., Andersson B. The high-energy proton beam as a neurosurgical tool. *Nature* 1958;**182**:1222-3.
- ⁵ Leksell L., Larsson B., Andersson B., Rexed B., Sourander P., Mair W. Lesions in the depth of the brain produced by a beam of high-energy protons. *Acta Radiol* 1960;**54**:251-64.
- ⁶ Leksell L., Larsson B., Rexed B. The use of high-energy protons for cerebral surgery in man. *Acta Chir Scand* 1963;**125**:1-7.
- ⁷ Leksell L. *Stereotaxis and Radiosurgery. An operative System*. Springfield, Charles Thomas. 1971.
- ⁸ Larsson B., Liden K., Sarby B. Irradiation of small structures through the skull. *Acta radiol Onicol Radiat Phys Biol* 1974;**13**:512-34.
- ⁹ Wennerstrand J., Ungerstedt U. Cerebral radiosurgery. II. An anatomical study of Gamma radiolesions. *Acta Chir Scand* 1970;**136**:133-7.
- ¹⁰ Leksell, L. A note on the treatment of acoustic tumours. *Acta Chir Scand* 1971;**137**:763-5.
- ¹¹ Steiner L., Leksell L., Greitz T., Forster DMC, Backlund E.-O. Stereotaxic radiosurgery for cerebral arterio-

Table 4 Stereotactic radiosurgery in arterio-venous malformations

Number of patients	Observation period	Total obliteration	Partial obliteration	No change
85	1 year	34 (40%)	34 (40%)	17 (20%)
67	2 years	56 (83.5%)	7 (10.5%)	4 (5.9%)

- venous malformations. Report of a case. *Acta Chir Scand* 1972;**138**:459-64.
- ¹² Bergström M, Greitz T. Stereotaxic computed tomography. *Am J Roentgenol* 1976;**127**:167-70.
- ¹³ Leksell L, Jernberg B. Stereotaxis and tomography. A technical note. *Acta Neurochir*. 1980;**52**:1-7.
- ¹⁴ Leksell L. Cerebral radiosurgery. I. Gammathalmotomy in two cases of intractable pain. *Acta Chir Scand* 1968;**134**:585-95.
- ¹⁵ Steiner L, Forster D, Leksell L, Meyerson B, Boëthius J. Gammathalamotomy in intractable pain. *Acta Neurochir*. 1980;**52**:173-84.
- ¹⁶ Leksell L. Stereotaxic radiosurgery in trigeminal neuralgia. *Acta Chir Scand* 1971;**137**:311-4.
- ¹⁷ Leksell L, Backlund E-O. Stereotaxic Gammacapsulotomy. In: Hitchcock, ER, Ballantine HT, Meyerson BA, eds. *Modern Concepts in Psychiatric Surgery*. Amsterdam: Elsevier/North-Holland Biomedical Press, 1979. 213.
- ¹⁸ Leksell L, Liden C. A therapeutic trial with radioactive isotopes in cystic brain tumour. In: *Radioisotope Techniques, Vol I*. Oxford: HM Stationery Office, 1953.
- ¹⁹ Backlund E-O. Stereotactic treatment of craniopharyngiomas—a 15-year material. Scand Neurosurg Soc 32nd ann meeting, Linköping, 1979. (Personal communication).
- ²⁰ Backlund E-O. Solid craniopharyngiomas treated by stereotactic radiosurgery. In: Szikla G, ed. *Stereotactic Cerebral Irradiation*. Insem Symposium no. 12, Amsterdam: Elsevier/North-Holland Biomedical Press 1979. 271-281.
- ²¹ Rahn T. *Stereotactic radiosurgery in Cushing's disease*. (Thesis), Sundt Offset, Stockholm 1980.
- ²² Cairns H. On conserving the facial nerve during removal of tumours of the cerebello-pontine angle. *Proc R Soc Med* 1931;**25**:1.
- ²³ Norén G. *Stereotactic radiosurgery in acoustic neurinomas. A new therapeutic approach*. (Thesis) Sundt Offset, Stockholm 1982.
- ²⁴ Hirsch A, Norén G, Andersson H. Audiologic findings after stereotactic radiosurgery in nine cases of acoustic neurinomas. *Acta Otolaryngol* 1979;**88**:155-60.
- ²⁵ Nilsson A, Wennerstrand J, Leksell D, Backlund E-O. Stereotactic gamma irradiation of basilar artery in cat. Preliminary experiences. *Acta Radiol Oncol* 1978;**17**:150-60.
- ²⁶ Steiner L, Leksell L, Forster DMC, Greitz T, Backlund E-O. Stereotaxic radiosurgery in intracranial arterio-venous malformations. *Acta Neurochir Suppl* 1974;**21**:195-209.
- ²⁷ Steiner L. Radiosurgery in arterio-venous malformations in the brain. In: Wilson C, Stein B, eds. *Current Neurosurgical Practice*. In press.

